

Evaluation of antifertility efficacy of *Carica papaya* seed extract through histological indices in Male Albino Rats

Hasim Basha S, Lalithamma A, Govardhan Naik A and Changamma C*.

Department of Zoology, S.V. University, Tirupati, Andhra Pradesh, India.

*Corresponding Author: E-Mail: challa1957@gmail.com

ABSTRACT

The oral administration of *Carica papaya* seed extract on histological studies revealed that the extract mainly shows the effect on disruption in the arrangement of seminiferous tubules, early spermatids and other spermatogenic cells. In epididymis the lumen contained fibroblasts with necrotic materials. The histology of seminal vesicle showed reduction in lumen size due to creeping in of mucosal folds and lowering of secretion. Histology of prostate gland shows the disintegration in various alveoli. The lumen had less secretory material in some follicles and the mucosal folds were damaged. The epithelium had degenerated cellular elements.

Keywords: *Carica papaya*. Testis. Spermatozoa. Histology. Male infertility.

1. INTRODUCTION

Many plants have been known to possess antifertility activity, but limited attempts have been made to scientifically evaluate these claims. It is thus, imperative that the male partner has access to a variety of contraceptive modalities. The major target sites for fertility regulation in the male reproductive tract are; testis, where spermatogenesis and sperm production occur, the use of antispermatogenic compounds which leads to oligospermia, azoospermia or abnormal production of spermatozoa, epididymis, where spermatozoa acquire progressive motility and fertilizing capacity (sperm maturation), this organ represents an ideal extra gonadal site for fertility regulation [1]. *Carica papaya* Linn. (family: Caricaceae) is a tropical tree which is native to the tropics of the Americas but now widely cultivated in other tropical regions of the world, for its edible melon-like fruit, which is available throughout the year [2]. *Carica papaya* Linn. (CPL) is a perennial, fast-growing, semi-woody tropical herb. At present research is going on very well upon the antifertility effect of *Carica papaya*. Several studies suggest that different parts (leaf & bark) of the papaya plant have been showing antifertility effect by reducing the sperm count, motility and spermatogenesis etc. The present study is aimed to evaluate the effect of papaya seed extract on structural organization of male reproductive organs.

2. MATERIALS AND METHODS

Healthy adult male Wistar strain albino rats (90 day old, weight 180±10g) were administered with 150 mg/kg body wt/day of ethanolic extract of papaya seed through oral route for 15 days. The ethanolic extract was prepared according to WHO (1983) [3] protocol CG-04. The seeds were shed-dried, powdered and extracted with 95% ethanol (v/v) at 55-60°C for 3 h. The solvent was distilled under reduced pressure; the resulting mass was dried under vacuum and kept at 24°C until use. The control animals were given normal saline or sterile distilled water. Both control and experimental rats were maintained under standard animal house facilities, with a temperature of 25±2°C, photoperiod of 12 hours light and 12 hours dark cycle, with a relative humidity of 50 ± 5% and fed on standard rat feed obtained from Hindustan Lever Ltd., Mumbai, India.

Twenty four hour after the last dose, the animals were autopsied and testes, epididymis, seminal vesicle and prostate gland were fixed immediately after isolation in Bouin's fluid for 24 hours. After 24 hours the organs were removed from Bouin's fluid and further fixed in fresh Bouin's fluid for another 72 hours. Each tissue was sliced athwart into slabs of about 0.5 cm thick and dehydrated in varying degree of alcohol (70%, 90%). From 90% alcohol to 3 changes of absolute alcohol for 1 hour each, then into chloroform for about 10 hours and later transferred into fresh chloroform for about 30 minutes. The tissues were placed in 3 changes of molten paraffin wax for 30

minutes each in an oven at 57 °C. They were placed vertically in molten paraffin wax inside a plastic mould and left overnight to cool and solidify. They were later trimmed and mounted on wooden blocks. Serial sections were cut using a rotary microtome at 5-micron thickness. Sections were floated in a water bath and picked by albumenized slides and dried on the hot plate at 52 °C. To stain, the slides were de-waxed in staining racks and placed in staining wells containing xylene and rehydrated in varying degree of alcohol (absolute, 90%, and 70%) and then to water for 5 minutes after which they were stained with haematoxyline for 3 minutes. Excess haematoxyline was washed off with water and differentiated with 1% acid alcohol. Sections were rinsed under running tap water and then left for 5 minutes for bluing. Sections were counterstained with 1% eosin and washed off with water. They were dehydrated with 70%, 90% and absolute alcohol and cleared in xylene to remove all traces of water. A drop of mountant was placed on the surface of the slide and covered with a 22 by 22 cm cover slip.

3. RESULTS AND DISCUSSION

3.1. Histological analysis of normal testes

The light microscopic examination of the testes in the control group normal histological profile in which the seminiferous tubules were surrounded by intertubular connecting tissues containing the interstitial cells of Leydig and blood vessels. Surrounding the germinal epithelium of the seminiferous tubules is a basement membrane on which rests actively dividing spermatogonia and sparsely distributed Sertoli cells whose apices reach the lumen of the tubules. The primary spermatocytes, secondary spermatocytes, early and late spermatid were seen arranged in a concentric manner from the basal layer of the spermatogonia towards the lumen of the seminiferous tubules as show in Slide 1; Fig. A & C.

3.2. Effect of extract on histology of testes

The testes of the Wistar albino rats treated with 150mg of *C. papaya* seed extract as shown in Fig. B. Histological studies revealed the extract mainly shows the effect on disruption in the arrangement of seminiferous tubules, showed depleted germinal epithelium. No late spermatids were seen but a few early spermatids in some sections along with the other spermatogenic cells. The seminiferous tubules were lined by only few necrotic germ cells with scattered Sertoli cells (Slide 1; Fig. D) which suggest that the treatment caused the reduction in the number of spermatozoa which leads to alterations in kinetics of spermatogenesis [4].

The seminiferous tubules presented significant degenerative changes. The changes invoked by the treatment consisted of the damage of the germinal epithelium and degeneration of spermatocytes and spermatids [5]. The interstitium was highly reduced. The tiered arrangement of the germ cells was disturbed and most of them were seen to have migrated into the lumen. Sloughing of the dead cells occurred into the lumen of the tubules. Hence sperm production and maturation process can be severely affected leading to the loss of fertility.

3.3. Histology of normal caput and cauda epididymis

The transverse section of epididymis presented a normal histological picture. The epithelial cells of the caput were tall, columnar with nuclei arranged in a row near the thin basement membrane (Slide 2 & 3; Fig. A & C).

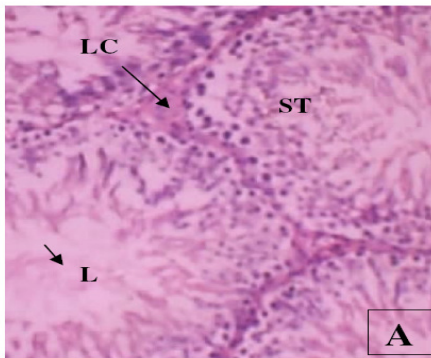
The epithelium of the cauda consisted of low cuboidal cells. The lumen of the ductules was larger in the cauda and smaller in the caput segments of stereocilia were more profuse in the caput region than in the cauda. Both the portions of the epididymis were full of spermatozoa (Slide 2; Fig. C). Intertubular connective tissue and vascularity was observed to be normal in both caput and cauda epididymis [6].

3.4. Effect of extract on histology of caput and cauda epididymis

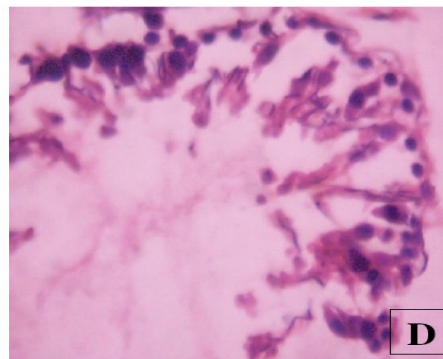
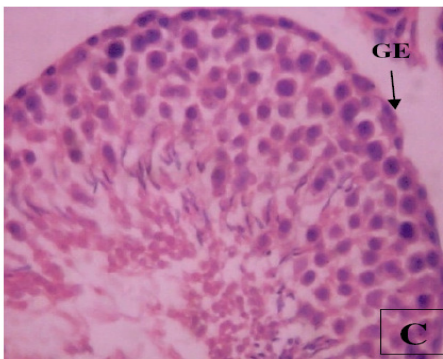
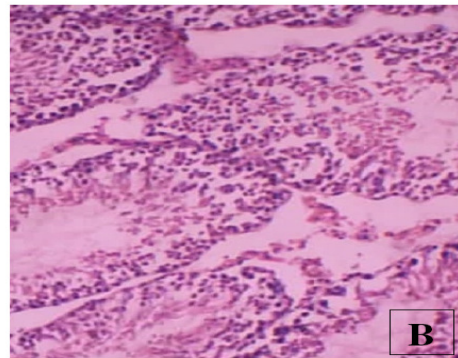
In experimental epididymis the destruction of the basement membrane observed [7]. Treated animals showed irregular shape and increased in size of the tubules, lumen contained fibroblasts with necrotic materials. There was also extensive fibrosis of the tubules and disruption of the epithelial lining (Slide 2&3; Fig. B). The lumen of ducts contained sperms with cellular debris. The interstitial spaces were filled with little loose connective tissue, which has clumped.

The histological alterations were more visible in caput than cauda. The inter tubular spaces were wider in caput and filled with some unknown material. The stereocilia were lacking in caput. In cauda, the epithelial cells were distorted and nuclear pyknosis appeared among the epithelial cells. The lumen of ducts contained cellular debris (Slide 2&3; Fig. B). The interstitial spaces were filled with loose connective tissue. No sperms were visible. In cauda there were very little spermatozoa which had clumped. The interstitial spaces were filled with little loose connective tissue, which has clumped. The interstitial spaces were filled with loose connective tissue.

T.S of Testes (Control)

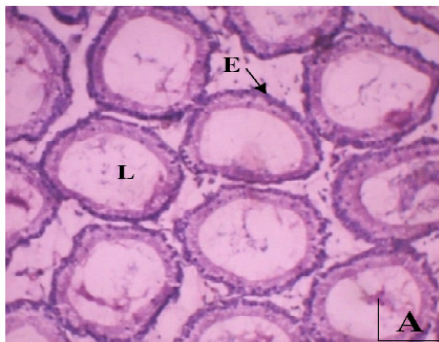

T.S of Testes (Carica papaya Extract Treated)

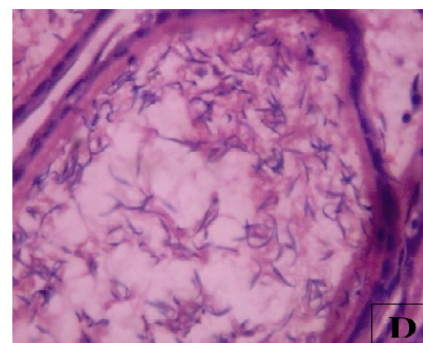
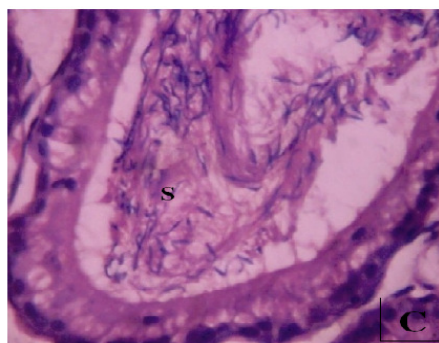
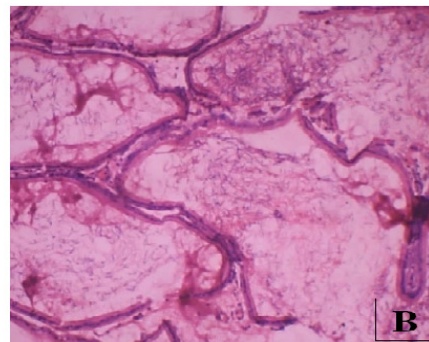


Slide - 1: (A & B are in Mag. X 10 ; C & D are in Mag. X 40 ; ST- Seminiferous tubule LC- Leydig cell; Stain: H & E; GE- Germinal epithelium; L- Lumen)

T.S of Caput Epididymis (Control)

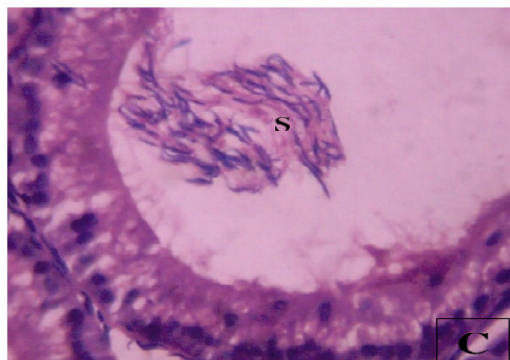
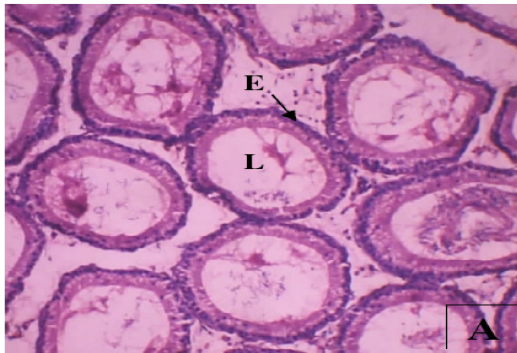

T.S of Caput Epididymis (Carica papaya extract Treated)

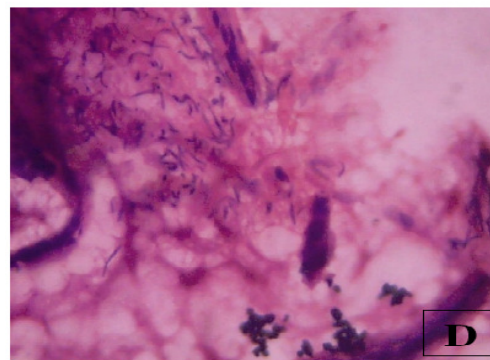
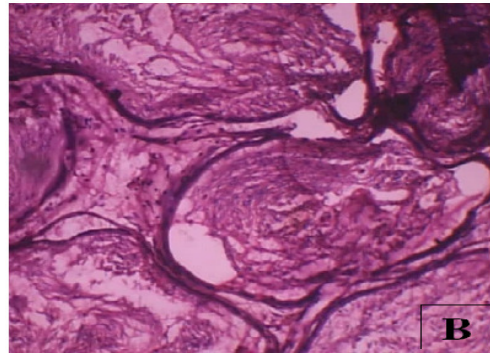


Slide - 2: (A & B are in Mag. X 10 ; C & D are in Mag. X 40 ; E- Epithelium; L- Lumen; S- Spermatozoa)

T.S of Cauda Epididymis (Control)

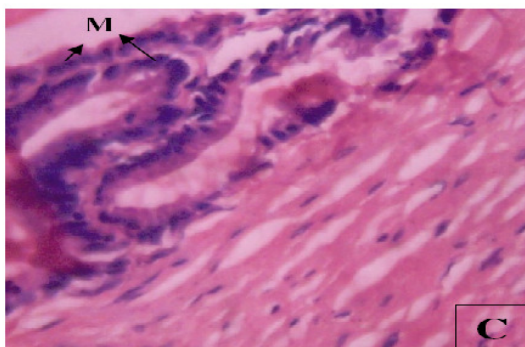
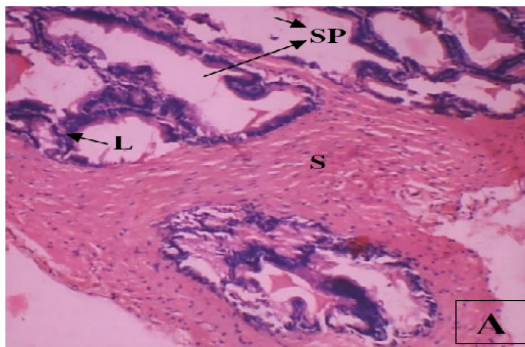


T.S of Cauda Epididymis (Carica papaya extractTreated)

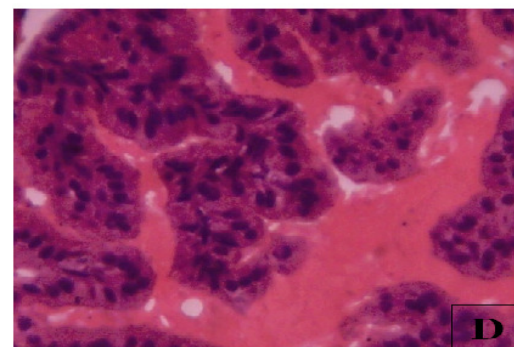
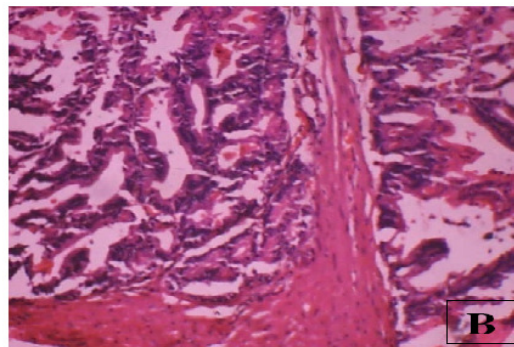


Slide - 3: (A & B are in Mag. X 10 ; C & D are in Mag. X 40 ; E- Epithelium; L- Lumen Stain: H & E; S- Spermatozoa)

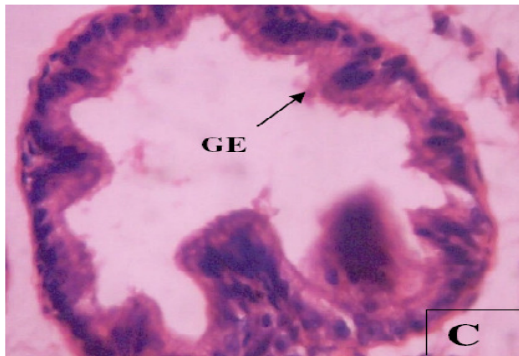
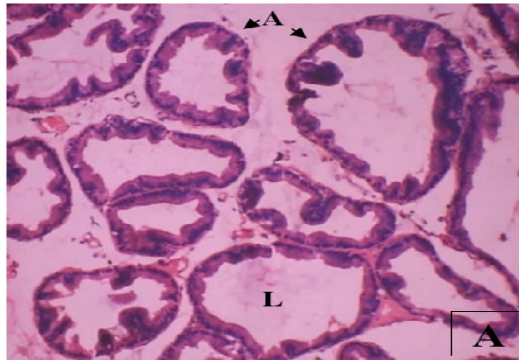
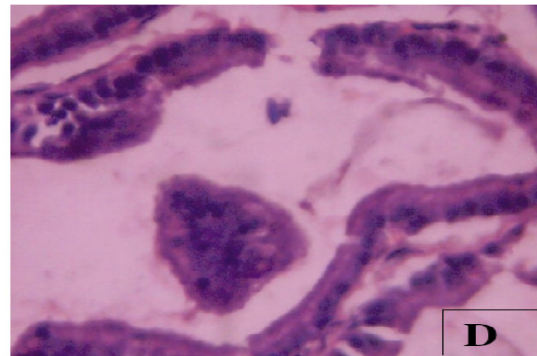
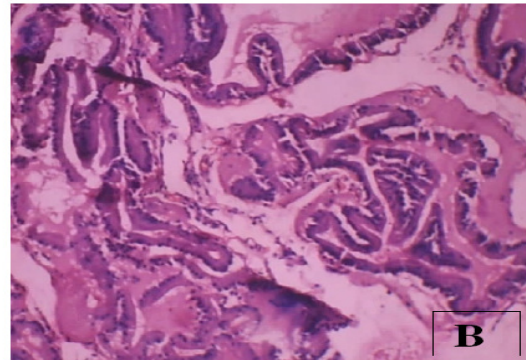
T.S of Seminal vesicle (Control)



T.S of Seminal vesicle (Carica papaya extractTreated)



Slide - 4: (A & B are in Mag. X 10 ; C & D are in Mag. X 40 ; SP- Secretory pockets L- Lamina propria; Stain: H & E; S- Smooth muscle; M- Mucosal folds)

T.S of Prostate gland (Control)**T.S of Prostate gland (Carica papaya extractTreated)**

Slide - 5: (A & B are in Mag. X 10 ; C & D are in Mag. X 40 ; A- Alveoli; L- Lumen with secretions; Stain: H & E; GE- Glandular Epithelium)

The histological changes were more pronounced in caput than in cauda region. In caput, the lumen of tubules contained little or no spermatozoa. The epithelial nuclei were observed to have migrated into the lumen of the tubules. In cauda, the intertubular spaces were widened and were observed to be filled with unidentifiable fibrous material [4].

3.5. Histology of normal seminal vesicle

The transverse section (T.S.) of seminal vesicle of control rats showed mucosal folds extending into the lumen. The lumen was filled with secretions produced by glandular epithelium (Slide 4; Fig A & C). The epithelial lining of mucosa consisted of a single layer of tall columnar cells with basal oval nuclei.

3.6. Effect of extract on histology of seminal vesicle

Reduction in lumen size due to creeping in of mucosal folds and lowering of secretion. The patterns of mucosal folds were highly distorted. The muscle layers were thin. The lamina propria and connective tissue were in poor condition (Slide 4; Fig. B).

The epithelial cells are changed their shape. The lamina propria and muscle layers were

disturbed and reduced in height. The mucosal crypts were no more discernible (Slide 4; Fig. D)[6].

3.7. Histology of normal prostate glands

The histological structure of the prostate gland in T.S. of control animals showed a number of alveoli lined by the low columnar epithelium with basal nuclei. The follicular lumen was full of secretions. There was an intervening fiber muscular stoma. The epithelium had proliferated into the crypts having invaded the lumen. Folding of the mucosal lining was observed in smaller tubules but distended tubules had no mucosal folds (Slide 5; Fig. A & C).

3.8. Effect of extract on histology of prostate glands

Administration of *C. papaya* seed extract produced significant alterations in the histological structure of prostate gland. The various alveoli were in the process of disintegration. The lumen had less secretory material in some follicles and the mucosal folds were damaged. The epithelium had degenerated cellular elements (Slide 4; Fig. B & D).

Acknowledgements

The authors were grateful to RGNF, MANF-UGC, New Delhi for financial support.

4. REFERENCES

1. Shivabasavaiah. Antifertility Effects of Madhuca Indica Leaves in Male Swiss Albino Rats. 2011; **Journal of Pharmacy Research** 2011; 4(2): 323-326.
2. Banerjee A. Antihyperlipidemic effect of Carica papaya L. in Sprague Dawley rats. **Nigerian Journal of Natural Products and Medicine**, 2006; 10: 69-72.
3. WHO: Protocol CG-40. Preparation of Alcoholic Extract for Bioassay and Phytochemical Studies. (**APJF/IP, 1001A**); 1983.
4. Sarwat Jahan. Histomorphological study to evaluate anti-fertility effect of *Abrus precatorius* L. in adult male mice. **Journal of Medicinal Plants**. 2009; 3(12): 1021-1028.
5. Nabil Azar Khouri and Zeyad EL-Akawi. Antiandrogenic activity of Ruta graveolens L in male Albino rats with emphasis on sexual and aggressive behavior. **Neuroendocrinology Letters**, 2005; 26(26).
6. Bhatia DK. Antifertility effects of crude different of Adiantum lunulatum Burm. On Reproductive Organs of male albino rats. **Biological Forum- An International Journal**, 2010; 2(2): 88-93.
7. Verma RJ and Chinoy NJ. Effect of papaya seed extract on contractile response of cauda epididyma Itubules. **Asian Journal of Andrology**, 2002; 4(1): 77-78.